



PATIENT

Bug Baker

SPECIES

Feline

BREED

DSH

SEX

Female Spayed

AGE

2.2 years

WEIGHT

7.16lbs

INTERPRETED BY

Maggie Machen Lamy,
DVM, DACVIM
(Cardiology)

IMAGING PERFORMED BY

Melinda Persson, DVM

HOSPITAL NAME

At Home Veterinary

REFERRING VET

Dr. Melinda Persson

INVOICE

47082

DATE

3/3/26

PRESENTING CLINICAL SIGNS

History: Recheck echo. Doing well.

-Pertinent previous echo findings (7/2025 MML): VSD; moderate diameter, left to right (5.0m/s). Mild LAE, no LVE. LA: 1.5.

ECHOCARDIOGRAM FINDINGS

2D, m-mode, color flow and doppler imaging is available. The left ventricular wall is normal in dimension. The LV chamber is mildly increased in diastole. A moderate diameter perimembranous VSD is seen just below the aortic valve. The shunt is left to right; max velocity 4.5m/s. No obvious right to left flow identified. The left atrium is mildly increased in size. The right atrium is normal in size. The right ventricle appears normal. The MPA is mildly dilated. The mitral valve is normal in structure and mobility. No MR/TR. Blood flow through both the LVOT and RVOT is normal in velocity. No AI. Mild PI. There is no pleural or pericardial effusion seen.

CARDIAC CHART

FELINE CARDIAC PARAMETERS	BODY WEIGHT (kg)	HR (BPM)	IVSd (cm) (Moise, Pipers)	LVIDd (cm) (Moise, Pipers)	LVWd (cm) (Moise, Pipers)	FS (%)	EF (%)
NORMAL PARAMETER	-----	150-240	0.35-0.55	<2 (mean 1.5)	3.5-0.55	35-67	80-100
PATIENT	3.2	NM	0.43	1.46	0.40	52	86
FELINE CARDIAC PARAMETERS	LA/AO (Boon)	LA/AO HEART BASE (Swe) (Abbott)	LA 2D short axis Base view (cm) (Abbott)		LVOT VEL (m/s)	RVOT VEL (m/s)	E max (m/s)
NORMAL	<1.5	<1.3	<1.2		<1.6	<1.3	<0.9
PATIENT	NM	1.5	1.2		0.7	1.5	NM

**Note: All measurements based upon multi-modal images and methods. An average value is reported.*
Adapted from June Boon, Veterinary Echocardiography, 1998
Abbott J & MacLean H JVIM 2006;20: 111-119, Moise et al. Am J Vet Res 47:1476, 1986. Pipers et al. Am J Vet Res 40:882, 1979.

INTERPRETATION OF THE FINDINGS & FURTHER RECOMMENDATIONS

Compared to the prior evaluation, findings are similar. The VSD remains high velocity and left to right with mild secondary volume overload. The remainder of the study is unremarkable with no additional issues identified.

Given these findings, no medications are clearly indicated. Monitoring is advised. Prognosis is guarded long-term; however, a lack of progression is always a good sign. Patient may be at risk for development of congestive signs, maglinant arrhythmias and/or sudden death in the future.

Anesthetic risk is considered mild at this time; however, judicious IV fluid rates are advised to avoid fluid overload. Additionally, drugs that stimulate heart rate should be avoided unless clinically necessary (glycopyrrolate, atropine). **A screening ECG is recommended prior to**



PATIENT

Bug Baker

SPECIES

Feline

BREED

DSH

SEX

Female Spayed

AGE

2.2 years

WEIGHT

7.16lbs

INTERPRETED BY

Maggie Machen Lamy,
DVM, DACVIM
(Cardiology)

IMAGING PERFORMED BY

Melinda Persson, DVM

HOSPITAL NAME

At Home Veterinary

REFERRING VET

Dr. Melinda Persson

INVOICE

47082

DATE

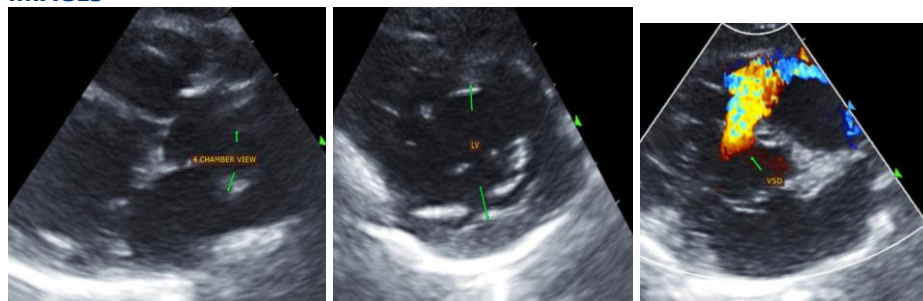
3/3/26

procedure however, as interventricular conduction abnormalities can be seen with septal defects. A reasonable protocol includes opioid/benzodiazepine premedication, propofol induction, isoflurane maintenance.

Monitor at home for any associated clinical signs, including respiratory changes or signs of a thrombus.

Recommend a recheck for progressive dilation annually, sooner if any clinical signs arise.

IMAGES



The information and recommendations provided are based on the images presented by the referring veterinarian. No evaluation can be communicated regarding pathology that was not visible in the image/video clips provided.

Thank you for this referral. This report was generated using transcription software, and minor dictation errors may be present. If the clinical or image interpretation does not parallel your findings or if I can be of any further assistance, please contact me.

Maggie Machen Lamy, DVM
Diplomate of the American College of Veterinary Internal Medicine (Cardiology)
info@sonopath.com